Mycotic Dermatitis in Common Bottlenose Dolphins (*Tursiops truncatus*) from Southern Brazil, with a Confirmed Record of Lobomycosis Disease

Ignacio B. Moreno[1], Paulo H. Ott[1-2], Maurício Tavares[1], Larissa R. Oliveira[1], Mauro R. Borba[3], David Driemeier[3], Sue B. Nakashima[1], Larissa S. Heinzelmann[4], Salvatore Siciliano[5] and Marie-Francoise Van Bressem[6]

1 - Grupo de Estudos de Mamíferos Aquáticos do Rio Grande do Sul (GEMARS) & Centro de Estudos Costeiros, Limnológicos e Marinhos da Universidade Federal do Rio Grande do Sul (CECLIMAR/UFRGS)
Rua Felipe Neri, 382 conj. 203, Auxiliadora, Porto Alegre, RS 90440-150, Brazil
gemars@gemars.org.br
2 - Universidade Estadual do Rio Grande do Sul (UERGS). Av. Mostardeiro, 3635. Cidreira, RS 95595-000, Brazil.
3 - Setor de Patologia Veterinária, Faculdade de Veterinária, Universidade Federal do Rio Grande do Sul. Avenida Bento Gonçalves, 9090 sala 29, Agronomia, Porto Alegre, RS 91540-000, Brazil.
4 - Laboratório de Imunogenética, Universidade Federal do Rio Grande do Sul (UFRGS), Brazil.
5 - Grupo de Estudos de Mamíferos Marinhos da Região dos Lagos, Departamento de Endemias, Escola Nacional de Saúde Pública (FIOCRUZ), Rua Leopoldo Bulhoes, 1480-6º. andar, Manguinhos, Rio de Janeiro, RJ, Brazil 21041-210 and Grupo de Estudos de Mamiferos Aquaticos da Amazonia (GEMAM), Projeto Piatam Oceano, Cenpes/Petrobras and Setor de Mastozoologia, Museu Paraense Emilio Goeldi, Belem, PA, Brazil.
6 - Cetacean Conservation Medicine Group (CMED-CEPEC), Museo de Delfines, Pucusana, Peru

Keywords: DISEASE, HABITAT, POLLUTANTS

ABSTRACT

The lobomycosis or lacaziosis is a chronic localized, cutaneous and subcutaneous infection caused by a dimorphic fungus (*Lacazia loboi*), that naturally affect humans and, at least, two dolphins species, the common bottlenose dolphin (*Tursiops truncatus*) and the boto-cinza (*Sotalia guianensis*). In cetaceans, the disease is widely distributed occurring from southern Brazil (Tramandaí River) to Gulf of Mexico and Atlantic coast of Florida. In the Southwest Atlantic, lobomycosis was first reported in a *T. truncatus* beached in 1990 in Laguna (28°30'S, 48°45'W), Santa Catarina State, Brazil. Photo-identification land based surveys were conducted from October 1991 to April 2008 in the Tramandaí estuary and from April 2003 to October 2004 in the Mampituba estuary. In addition to the photo-identification studies, regular monitoring beach surveys were conducted since October 1991 along the northern coast of the Rio Grande do Sul state. According to GEMARS database up to April 2008, 1,300 carcasses of marine mammals were collected. In Tramandaí estuary we observed lobomycosis and lobomycosis like disease (LLD) in two (20%) of the ten dolphins photo-identified. In Mampituba estuary we observed LLD in one (16.67%) of the six dolphins photo-identified, but this prevalence is likely to high as this community may reach 15 dolphins. From the period October 1991 to February 2008 a total of 65 *T. truncatus* carcasses were recovered, representing the second most common small cetacean in the area (5% out of 1,300). Altogether, stranding data and photo-id studies have provided one particular case of lobomycosis and 6 cases of undetermined mycotic diseases, including LLD, in free ranging bottlenose dolphins from Rio Grande do Sul state coast. The recent and accelerated degradation process of the estuarine areas from southern Brazil may have contributed to enhance the pathogenicity of mycotic diseases. In addition, special attention is necessary towards the bottlenose dolphin populations affected by lobmycosis in Southern Brazil. These populations are relatively small and unique due to the cooperative behaviour with artisanal fishermen.

INTRODUCTION

The lobomycosis or lacaziosis is a chronic localised, cutaneous and subcutaneous infection caused by a dimorphic fungus (*Lacazia loboi*), that naturally affect humans and at least two species of dolphins, the common bottlenose dolphin (*Tursiops truncatus*) and the boto-cinza (*Sotalia guianensis*) (Mendoza *et al.* 2001; Reif *et al.* 2006). The disease manifests as keloids, verrucoid to nodular lesions, crusty plaques, and tumors. The fungus grows as globose cells that are connected to each other by a narrow neck (Reif *et al.* 2006; Taborda *et al.* 1999). This pathology was recently found to be phylogenetic related to *Paracoccidioides brasiliensis* and to the other fungal dimorphic members of the Order Onygenales (Herr *et al.* 2001). The *L. loboi* cannot be cultured "in vitro" and is considered an obligatory parasite, fact that shows a tendency to reduction of the saprobic form of the fungus in nature (Herr *et al.* 2001; Taborda *et al.* 1999).

The first record of this infection was described by the Brazilian dermatologist Jorge Lobo in 1931 from a patient from Acre (northern Brazil). Since then, the condition was denominated as Lobo disease or lobomycosis and recently as lacaziosis (Brito & Quaresma 2007; Honda *et al.* 2007; Vilela *et al.* 2005). The disease in humans is limited to some countries in South America (Brazil n=318, Colombia n=50, Suriname n=34, Venezuela n=23, Costa Rica n=21, French Guiana n=16, Panamá n=13, Peru n=4, Bolivia n=3, Ecuador n=2, Guiana n=2, Mexico n=1), as well few cases in Europe, Canada and Unites States (Brito & Quaresma 2007). However, the anomalous cases outside Latin America was only documented in persons who had been travel to endemic areas (Reif *et al.* 2006) .

In dolphins, the disease is widely distributed occurring from southern Brazil (Tramandaí River) to Gulf of Mexico and Atlantic coast of Florida (Reif *et al.* 2006; Van Bressem *et al.* in press). In South western Atlantic Ocean the lobomycosis was first reported from a bottlenose dolphin beached in 1990 in Laguna (28°30'S, 48°45'W), Santa Catarina State in southern Brazil (Reif *et al.* 2006; Simões-Lopes *et al.* 1993). This was the only case known until recently when the apparent re-emergence of lobomycosis and lobomycosis-like disease (LLD) in coastal dolphins from Colombia, Ecuador, Peru and Brazil was reported (Bermúdez-Villapol *et al.* in press; Van Bressem *et al.* in press).

In this study, we describe the occurrence of mycotic diseases in seven dolphins, including a confirmed case of lobomycosis in *T. truncatus* from coastal populations in southern Brazil.

MATERIAL AND METHODS

The study area is situated in northern coast of the Rio Grande do Sul State in Southern Brazil (Figure 1). This region is located in the Subtropical Convergence and presents an influence of two currents: the Brazilian Current, transporting tropical water (temperature >20°C and salinity >36.00‰) and the Malvinas Current transporting subantarctic waters (temperature 4 to 15°C and salinity 33.70 to 34.15‰) (Seeliger *et al.* 1997). The area is characterized by an open coast that extends for more than 600 km, dominated by waves and microtides of 0,47m, with an extensive continental shelf (Gruber *et al.* 2006). In the northern coast area only two estuaries are present: the Tramandaí lagoon system (29°58'S, 050°07'W) and the Mampituba river (29°19'S; 049°43'W).

The Tramandaí Lagoon, with a 30km^{2} area, is connected to the Atlantic Ocean through a channel 1.5km long and 0.3km wide. Average depth is 1.5m in the lagoon and 5m in its channel (Schwartzbold & Schafer 1984). The Mampituba River, with approximately 0.5km^{2}, is located at the northernmost portion of the Rio Grande do Sul State coast. The size of its channel is 8km length and 300m wide. The average depth in its estuarine zone is 8m (Mendoza-Carranza & Vieira 2008). The environmental conditions of both estuaries changes dramatically over short time periods and throughout year, since this area is largely influenced by abrupt shifts in wind velocity and direction (Seeliger 2000).

Photo-identification land based surveys were conducted from 1991 to 2008 in the Tramandaí estuary and from 1995 to 2008 in the Mampituba estuary. Each survey lasted for a minimum of one hour and were conducted in good weather conditions (Beaufort Scale = 0-1). Dolphins were directly observed for 120 and 10 days in Tramandaí and Torres, respectively, resulting in over 2000 pictures. A 35mm reflex camera using printed films and with a 300mm zoom lens was used till 2004 and subsequently replaced by digital cameras with 300 and 400mm lenses. Photographs were taken at distances ranging from three meters to 25m with shutter speeds ranging between 1/500s to 1/2000s. It is important to notice that bottlenose dolphins inhabiting the Tramandaí

and Mampituba estuaries take part of a cooperative fishing for mullet (*Mugil* sp.) for at least several decades (Hoffmann 2004; Simões-Lopes *et al.* 1998; Tabajara 1992).

In addition to the photo-identification studies, common bottlenose dolphins were collected during systematic beach surveys of northern Rio Grande do Sul State coast, southern Brazil, along 270km of sandy beaches from Torres (29º19'S; 049º42'W) to National Park of Lagoa do Peixe (31º21'S; 051º02'W). These surveys were initiated in 1991 as part of a project to evaluate marine mammal and sea turtle fauna in the area. The surveyed area encompasses the whole northern coast of Rio Grande do Sul and the northern portion of the Mostardas Peninsula. According to GEMARS database up to April 2008, 1,300 carcasses of marine mammals were collected on the beach (GEMARS, unpublished data). Small cetaceans comprised some 57% of the total amount of carcasses, represented by franciscana (*Pontoporia blainvillei*), common bottlenose dolphin (*T. truncatus*), rough-toothed dolphin (*Steno bredanensis*), common dolphin (*Delphinus* sp.), Atlantic spotted dolphin (*Stenella frontalis*), striped dolphin (*S. coeruleoalba*), Fraser's dolphin (*Lagenodelphis hosei*), Risso's dolphin (*Grampus griseus*), long-finned pilot whale (*Globicephala melas*), killer whale (*Orcinus orca*) and false killer whale (*Pseudorca crassidens*).

Most carcasses were routinely necropsied on site for collecting samples for life-history analyses. Whenever possible, each fresh carcass was brought to the Centro de Estudos Costeiros, Limnológicos e Marinhos (CECLIMAR/UFRGS) facilities. During the necropsy standard measurement and external and internal examination were performed (Geraci & Lounsbury 2005; Norris 1961). Biological samples from different tissues were also collected and preserved in 10% formalin for pathological analysis. In the laboratory, formalin-fixed tissues were prepared, mounted and sections of 5µm were stained with haematoxylin and eosin (H&E) for most of the tissues. Special stain (Gridley fungus stain) was also used for the examination of the skin lesions. All samples and skeletons are deposited in the collection of the Grupo de Estudos de Mamíferos Aquáticos do Rio Grande do Sul (GEMARS), based in Porto Alegre, Brazil. Here we defined LLD as a mycotic disease very similar macroscopically to lobomycosis, in the absence of a histological diagnosis.

RESULTS

Photo-id studies

During the 17 years period of study in Tramandaí about 15 different dolphins were photo-identified in the area. However, the maximum number of dolphins in the Tramandaí estuary since 1991 remains about ten which can be the carrying capacity of the area. In Tramandaí estuary we observed lobomycosis-like disease (LLD) in two (20%) of the ten dolphins known in this area in 2003.
In Mampituba estuary we observed LLD in one (16.67%) of the six dolphins photo-identified since 1995. The total number of dolphins in Torres is unknown although the population may reach 15 dolphins (GEMARS unpublished data)(Bernardi & Freitas 2000).

Strandings

From the period October 1991 to February 2008 a total of 65 *T. truncatus* carcasses were recovered, representing the second most common small cetacean in the area (5% out of 1,300). From all stranded bottlenose dolphins, four (6.15 %) presented epidermal lesions.

Altogether, stranding data and photo-id studies have provided one particular case of lobomycosis and six cases of mycotic diseases, including LLD, in free ranging bottlenose dolphins from Rio Grande do Sul state coast. As they deserve special attention they will be treated separately in a chronological order:

Case report 1 – GEMARS 0258 – Mycosis

In 19 June 1995, a stranded bottlenose dolphin was found dead in Imbé. The dolphin, a 309cm female, presented several verrucoid and nodular skin lesions in the right pectoral fin, around the axillary region, in the dorsal fin, in the flanks, head and the ventral region (Figure 2 & 3).

Case Report 2 – GEMARS 0286 - Mycosis

In 25 October 1995, a stranded bottlenose dolphin was found dead in Miriápolis (29º 52'S; 050º 4'W). The dolphin was a female with 271cm of total length. This animal had several verrucoid lesions in the flukes (figure 4 & 5).

Case report 3 – "Pomba" - LLD
A bottlenose dolphin resident of the Tramandaí estuary known as "Pomba" by local fishermen at least since 1955 (Tabajara 1992). It was observed regularly in the estuary since 1989 as he interacted frequently with the mullet cooperative fishery (Simões-Lopes *et al.* 1998). Epidermal lesions (LLD) in this dolphin were first noticed on its dorsal fin in May 1999 (Figure 6). Since then skin lesions progressively increase over the body. The dolphin was last sighted and photographed in August 2003 (Hoffmann, 2004), and probably died since.

Case report 4 - "Lobisomem" (GEMARS 1259) - Lobomycosis
A dolphin called "Lobisomem" by local fishermen was first photo-identified in October 1992 in Tramandaí estuary. This dolphin was also regularly observed in subsequent years interacting with the mullet cooperative fishery. Skin lesions were first noticed in December 2002 (Figure 7) as ulcerations along the beak. Those evolved as widespread keloids, verrucoid and nodular skin lesions over the flank and tailstock in subsequent years until its death in November 2005 (Figure 8a,b). Diagnosis of lacaziosis was confirmed by clinical and histopathological analyzes of the carcass. This dolphin was a fully mature 339cm male at the time of its death. The skull, mandibles, teeth, complete skeleton was collected and deposited under collection number GEMARS 1259

The results of histopathology analysis from different tissues of this specimen are described below.

Skin: **Hematoxylin and eosin stain – H&E:** occurrence of hyperkeratosis, acanthosis and epithelial ulceration. Presence of diffuse and severe granulomatous inflammatory reaction composed mainly by histiocytes, neutrophils and giant cells with areas of cellular necrosis, which extends from epidermis to dermis, associated with a large number of fungal structures poorly stained. These fungal cells are usually round to oval and of relative uniform size. They connect each other with short "bridges" or tube-like structures forming chains of 2-5 cells each. Some individual cells and multiple buds are also seen (Figure 9a).
Gridley fungus stain – GF: presence of a large number of individual and chains of fungal cells well delineated and intensely stained in red, compatible with *Loboa loboi* (Figure 9b).
Liver: diffuse and mild paracentral necrosis and multifocal and mild periportal neutrophilic hepatitis.

Kidney, intestine, stomach, cardiac muscle, spleen and bladder: no significant microscopic alteration.

Case report 5 – GEMARS 0934 - LLD
In 22 January 2003, a stranded bottlenose dolphin was found dead near the Lagoa do Peixe National Park (31°17'S; 50°57'W). The dolphin, a 232 cm male, presented several verrucoid and nodular skin lesions over the right lobe of the tail.

Case report 6 – "Craquento" - LLD
A bottlenose dolphin from the Mampituba estuary, called "Craquento" was first photo-identified in September 2003 with small lobomycosis-like lesions in the flanks. Six months later, in March 2004, this dolphin was photographed in the same estuary with several lesions in the skin (Figure 10). The lesions were widespread in different part of the body and were clearly visible in the proximal region of the rostrum, the head, dorsum, both flanks and the caudal peduncle. It should be emphasized that "Craquento" was observed in association with "Lobisomen" (case report # 2) in the Tramandaí River, about 80km south of Torres estuary (Hoffmann 2004). Since then, "Craquento" was not seen again.

Case report 7 – GEMARS 1298 - Mycosis
In 15 February 2008, a stranded bottlenose dolphin was found dead in Xangri-Lá (29°48'S; 050°02'W). The dolphin, a 308cm female, presented four small (1-2 cm) wounds on the left flank (Figure 11). The histopathological analyzes showed that the lesions were caused by an unidentified fungus.

DISCUSSION

The case studies reported here are of special concern for the epidemiology of lobomycosis, LLD and other micotyc diseases in cetaceans. Since the first descriptions of lobomycosis in bottlenose dolphins of Florida, USA in the early 1970s (Caldwell *et al.* 1975; Migaki *et al.* 1971; Woodard 1972) and Brazil in 1990 (Simões-Lopes *et al.* 1993), and more recently by Flores *et al.* (2007; in press), our findings adds a considerable amount of information for a poorly known disease. In fact, we provide a full description of a confirmed case of lobomycosis in *Tursiops*. In addition we provide further detailed information on the recent cases of LLD

reported to Rio Grande do Sul, Brazil (Van Bressem *et al.* in press). Moreover new cases of skin lesions caused by an unidentified fungus are also described.

The cases reported here are a real evidence of re-emergency of lobomycosis disease in southern Brazil bottlenose dolphins' populations, nine years after the first report. The second case in Brazil, listed as Case Report 3 in this study, was from Tramandaí, an estuary 210km south of Laguna. Möller *et al.* (1994) described one *T. truncatus* photo-identified in Tramandaí were re-sighted in Mampituba and Laguna, over 200km north of its original site. This fact strongly suggests that *T. truncatus* individuals are in contact between populations living in different sites along southern Brazil.

The evidence of LLD in other three bottlenose dolphins (Report Cases #3, #5 and #6), two of them from the Tramandaí and Mampituba estuaries could indicate a high prevalence of lobomycosis in these populations. Reif *et al.* (2006) have considered as epidemic the lobomycosis observed in the southern population of *T. truncatus* in the Indian river Lagoon, Florida USA, with a prevalence of 30%. These authors have pointed out that the northern population of dolphins as well as the Charleston one has not presented skin disorders. It is important to mention that these populations of bottlenose dolphin are separated by one hundred kilometres.
Similarly, in the bottlenose dolphin populations of southern Brazil, lobomycosis and LLD have only been positively described in the northern Rio Grande do Sul individuals. In the southern population inhabiting the estuary of Lagoa dos Patos (32°09´S; 052°05´W), located at 310Km south of Tramandaí, there is no evidence of skin disorders or LLD in *Tursiops* (E.R. Secchi pers. comm). It should be emphasized that the Lagoa dos Patos population has been accompanied since 1993 and was estimated by mark-recapture studies at approximately 100 individuals (Dalla Rosa 1999).

In all cases reported in southern Brazil, there seems to be environment factor or condition linked to the re-emergency of lobomycosis or LLD in dolphins. The environmental factors associated to the occurrence of *L. loboi* seems to be tropical temperature (19 to 34°C), heavy rain regime (1,000 to 2,000 mm/year), humidity and abundant drainage basin (Brito & Quaresma 2007). Except for slightly lower temperatures in the winter, all the localities in southern Brazil indicated in this study fulfil these criteria. In addition, coastal degradation, including biological and chemical pollution, overfishing and boat traffic, may have contributed in lowering the immune response of the dolphins and these conditions could favour disease emergence. In common, Tramandaí, Mampituba and Laguna are subtropical estuaries, contaminated by agricultural and domestic runoff (Haase *et al.* 2003; SDM 1998). For these reasons the estuarine areas from southern Brazil are facing an increasing degradation process in recently years that could result in enhancing of the pathogenicity of diseases like lobomycosis and other mycotic diseases. These diseases could affect these small estuarine populations, as well the coastal dolphins that inhabit the Rio Grande do Sul inshore/offshore area. After the death of the dolphins reported here (cases #3, #4 and #6), until April 2008, there is no evidence of any other dolphin with lobomycosis or LLD in the estuaries of Tramandaí and Mampituba rivers. Therefore, a special attention is necessary towards the bottlenose dolphin populations affected by lobmycosis in Southern Brazil. These populations are relatively small and unique due to the cooperative behaviour with artisanal fishermen and coastal degradation could compromise the long term survival of these populations.

ACKNOWLEDGEMENTS

The Project: "Research and Conservation of Aquatic Mammals and Sea Turtles in the Rio Grande do Sul" (Pesquisa e Conservação de Mamíferos Marinhos e Tartarugas Marinhas no Litoral Norte do Rio Grande do Sul.), was supported by Fundação O Boticário de Proteção à Natureza, Cetacean Society International, Yaqu Pacha Foudation, Fundo Nacional do Meio Ambiente – FNMA and CNPq. We tanks Daniel Danilewicz, Rodrigo Machado, Cariane Campos Trigo, Janaína C. Wickert, Federico Sucunza, Daniela Hoss, Amanda Giacomo, Jonathas Barreto for collaborating in the collection and necropsies of the specimens. This is the GEMARS contribution number 27.

REFERENCES

Bermúdez-Villapol, L. A., Sayegh, A. J. and Bressem, M.-F. V. in press. Lobomycosis-like disease in a bottlenose dolphin (*Tursiops truncatus*) from Venezuela. Paper SC/60/DW presented to the IWC Scientific Committee, May 2008 (unpublished). 7pp. [Avaliable from the Office of this Journal].

Bernardi, L. R. and Freitas, T. R. O. 2000. Uso de fotoidentificação para o reconhecimento individual do boto, *Tursiops truncatus* (Cetacea, Delphinidae) no Rio Mampituba, Torres, RS. *in:* 9a Reunión de Trabajo de Especialistas en mamíferos aquáticos de America del Sur, Buenos Aites. p:13.

Brito, A. C. D. and Quaresma, J. A. S. 2007. Lacaziose (doença de Jorge Lobo): revisão e atualização. *An. Bras. Dermatol.*, 82(5):461-474.

Caldwell, D. K., Caldwell, M. C., Woodard, J. C., Ajello, L., Kaplan, W. and McClure, H. M. 1975. Lobomycosis as a Disease of Atlantic Bottle-Nosed Dolphin (*Tursiops truncatus* Montagu, 1821). *Am. J. Trop. Med. Hyg.*, 24(1):105-114.

Dalla Rosa, L. 1999. *Estimativa do tamanho da população de botos, Tursiops truncatus, do estuário da Lagoa dos Patos, RS, a partir da fotoidentificação de individuos com marcas naturais e da aplicação de modelos de marcação-recaptura*. Universidade de Rio Grande, Master Thesis. [Avaliable from author].

Flores, P. A. C., Bazzalo, M., Zago, L. and Wells, R. S. 2007. Epidermal disorders and insights on residency in free-ranging bottlenose dolphins (*Tursiops truncatus*) off southern Brazil. . Paper SC/59/DW3 presented to the IWC Scientific Committee, May 2007 (unpublished). [Avaliable from the Office of this Journal].

Flores, P. A. C., Bazzalo, M., Zago, L. and Wells, R. S. in press. Insights on epidermal disorders and residency in free-ranging bottlenose dolphins (*Tursiops truncatus*) off southern Brazil. *Biotemas*,

Geraci, J. R. and Lounsbury, V. J. (ed). 2005. *Marine Mammals Ashore: a field guide for strandings*. National Aquarium in Baltimore, Baltimore. 371pp.

Gruber, N. L. S., Correa, I. C. S., Nicolodi, J. L. and Barboza, E. G. 2006. Morphodynamic limits of shoreface and inner shelf at the northern coast of Rio Grande do Sul, Brazil. *J. Coast. Res. Spec. Issue*, 2(1):664-668.

Haase, J., Stringuini, M. H., Silva, M. L. B. C., Rodrigues, M. L. K. and Koch, S. M. V. 2003. Qualidade das águas superficiais do litoral norte e médio do Rio Grande do Sul. *in:* 22º Congresso Brasileiro de Engenharia Sanitária e Ambiental, Joinville, Brasil. p:17.

Herr, R. A., Tarcha, E. J., Taborda, P. R., Taylor, J. W., Ajello, L. and Mendoza, L. 2001. Phylogenetic Analysis of *Lacazia loboi* Places This Previously Uncharacterized Pathogen within the Dimorphic Onygenales. *J. Clin. Microbiol.*, 39(1):309.

Hoffmann, L. S. 2004. *Um estudo de longa duração de um grupo costeiro de golfinhos Tursiops truncatus (Montagu, 1821) (Cetacea, Delphinidae) no sul do Brasil: aspectos de sua biologia e bioacústica*. Universidade Federal do Rio Grande do Sul, Ph.D. Thesis. Porto Alegre. [Avaliable from author].

Honda, K., Horner, K. and Raugi, G. J. 2007. Lobomycosis. 09/April/2008. [Available from http://www.emedicine.com/derm/topic832.htm].

Mendoza-Carranza, M. and Vieira, J. 2008. Whitemouth croaker *Micropogonias furnieri* (Desmarest, 1823) feeding strategies across four southern Brazilian estuaries. *Aquat. Ecol.*, 42(1):83-93.

Mendoza, L., Ajello, L. and Taylor, J. W. 2001. The taxonomic status of *Lacazia loboi* and *Rhinosporidium seeberi* has been finally resolved with the use of molecular tools. *Rev. Iberoam. Micol.*, 18(1):95–98.

Migaki, G., Valerio, M. G., Irvine, B. and Garner, F. M. 1971. Lobos disease in an Atlantic bottle-nosed dolphin. *Lobos disease in an Atlantic bottle-nosed dolphin*, 159(5):578-582.

Moller, L., Simões-Lopes, P. C., Secchi, E. R. and Zerbini, A. N. 1994. Uso de fotoidentificação no estudo do deslocamento de botos, *Tursiops truncatus* (Cetacea, Delphinidae), na costa sul do Brasil. *in:* VI Reunião de Trabalho de Especialistas em Mamíferos Aquáticos da América do Sul, Florianópolis, SC. p:24-28.

Norris, K. S. 1961. Standardized methods for measuring and recording data on the smaller cetaceans. *J. Mamm.*, 42(4):471-476.

Reif, J. S., Mazzoil, M. S., McCulloch, S. D., Varela, R. A., Goldstein, J. D., Fair, P. A. and Bossart, G. D. 2006. Lobomycosis in Atlantic bottlenose dolphins from the Indian River Lagoon, Florida. *Lobomycosis in Atlantic bottlenose dolphins from the Indian River Lagoon, Florida*, 228(1):104-108.

Schwartzbold, A. and Schafer, A. 1984. Genese e Morfologia das Lagoas Costeiras do Rio Grande do Sul, Brasil. *Amazoniana*, 9(1):87-104.

SDM, 1998 Diagnóstico dos recursos hídricos e organização dos agentes da Bacia Hidrográfica do Rio Tubarão e Complexo Lagunar. In: *http://www.comitetubarao.unisul.br/gruperh/meio-ambiente.html*: 163. Secretaria de Estado do Desenvolvimento Urbano e Meio Ambiente, Florianópolis, SC, Brazil.

Seeliger, U. 2000. The Patos Lagoon estuary, Brazil. 167–182. *In*: U. SeeligerandV. Kjerfve *Coastal Marine Ecosystems of Latin America*: Springer Verlag, Berlin.

Seeliger, U., Odebrecht, C. and Castello, J. P. (ed). 1997. *Subtropical Convergence Environments - The Coast and Sea in the Southwestern Atlantic*. Springer-Verlag Berlin. 332pp.

Simões-Lopes, P. C., Fabián, M. E. and Menegethi, J. O. 1998. Dolphin interactions with the mullet artisanal fishing on southern Brazil: a qualitative and quantitative approach. *Rev. Bras. Zool.*, 15(3):709-726.

Simões-Lopes, P. C., Paula, G. S., Both, M. C., Xavier, F. M. and Scaramello, A. C. 1993. Fist Case of Lobomycosis in a Bottlenose Dolphin from Southern Brazil. *Mar. Mamm. Sci.*, 9(3):329-331.

Tabajara, L. 1992. Aspectos da relação pescador-boto-tainha no estuário do Rio Tramandaí-RS. 17-49. *In*: E. PadilhaandH. Trindade *Os Botos do Rio Tramandaí*: Prefeitura Municipal de Tramandaí & Universidade Federal do Rio Grande do Sul, Tramandaí 76pp.

Taborda, P. R., Taborda, V. A. and McGinnis, M. R. 1999. Lacazia loboi gen. nov., comb. nov., the Etiologic Agent of Lobomycosis. *J. Clin. Microbiol.*, 37(6):2031-2033.

Van Bressem, M. F., Van Waerebeek, K., Reyes, J., Félix, F., Echegaray, M., Siciliano, S., Di Beneditto, A. P., Flach, L., Viddi, F., Avila, I. C., Herrera, J. C., Tobón, I. C., Bolaños-Jiménez, J., Moreno, I. B., Ott, P. H., Sanino, G. P., Castineira, E., Montes, D., Crespo, E., Flores, P. A. C., Haase, B., Souza, S. M. F. M., Laeta, M. and Fragoso, A. B. in press. A preliminary overview of skin and skeletal diseases and traumata in small cetaceans from South American waters. *LAJAM*,

Vilela, R., Mendoza, L., Rosa, P. S., Belone, A. F. F., Madeira, S., Opromolla, D. V. A. and Resende, M. A. 2005. Molecular model for studying the uncultivated fungal pathogen *Lacazia loboi*. *J. Clin. Microbiol.*, 43(8):3657-3661.

Woodard, J. C. 1972. Electron microscopic study of lobomycosis (*Loboa loboi*). *Lab. Invest.*, 27(6):606-612.

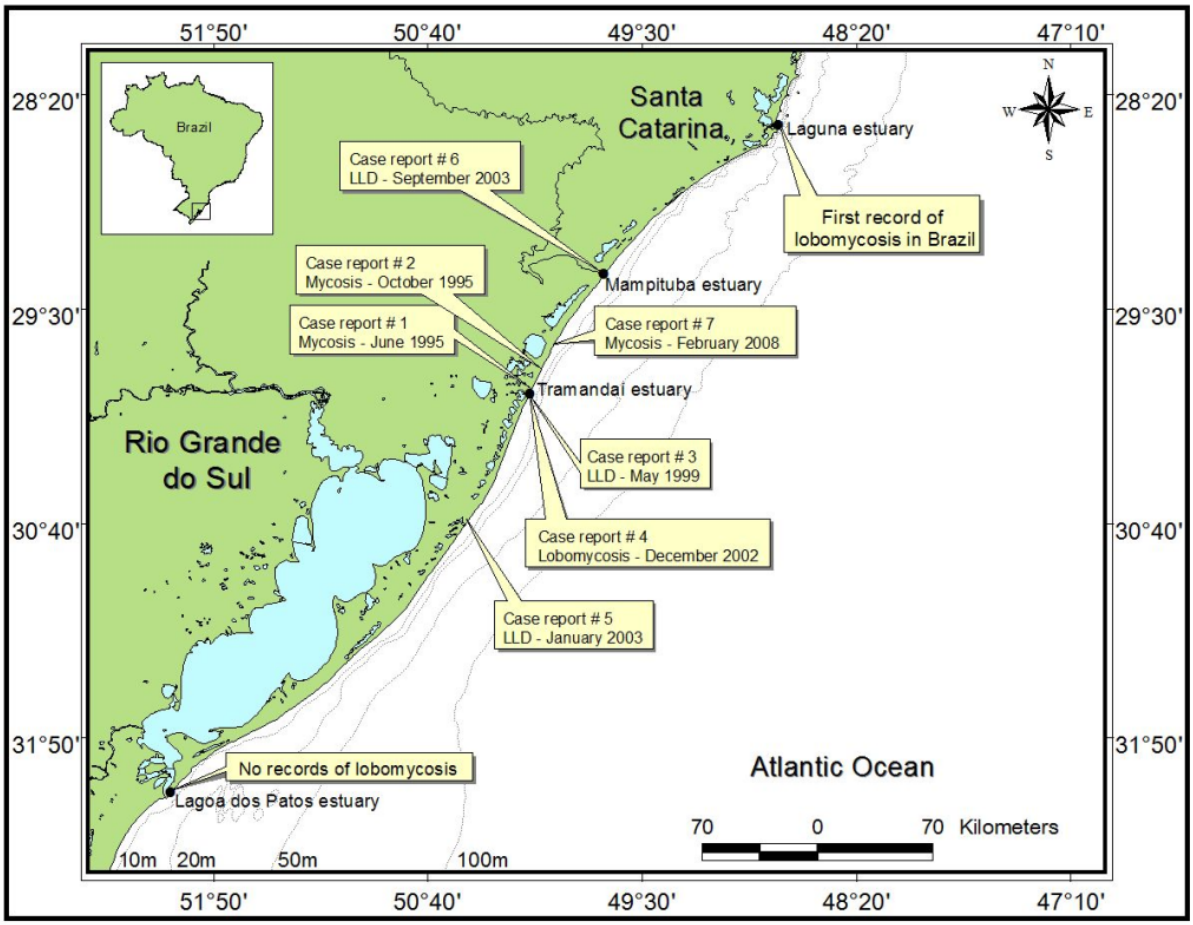

Figure 1 – Study area and known cases of lobomycosis, mycosis and LLD in southern Brazil

Figure 2 – Overall view of GEMARS 0258 showing the ulcerations in the body – © Paulo Ott/GEMARS

Figure 3 – Detail of pectoral fin of GEMARS 0258 with lesions – © Paulo Ott/GEMARS

Figure 4 – Overall view of GEMARS 0286 showing the ulcerations in the fluke – © Paulo Ott/GEMARS

Figure 5 – Detail of flukes of GEMARS 0286 – © Paulo Ott/GEMARS

Figure 6 – Dolphin “Pomba” with lesions in dolsal fin. © Ignacio Moreno/GEMARS

Figure 7 – Skin lesion in the Dolphin “Lobisomen” in December 2002 – © Ignacio Moreno/GEMARS

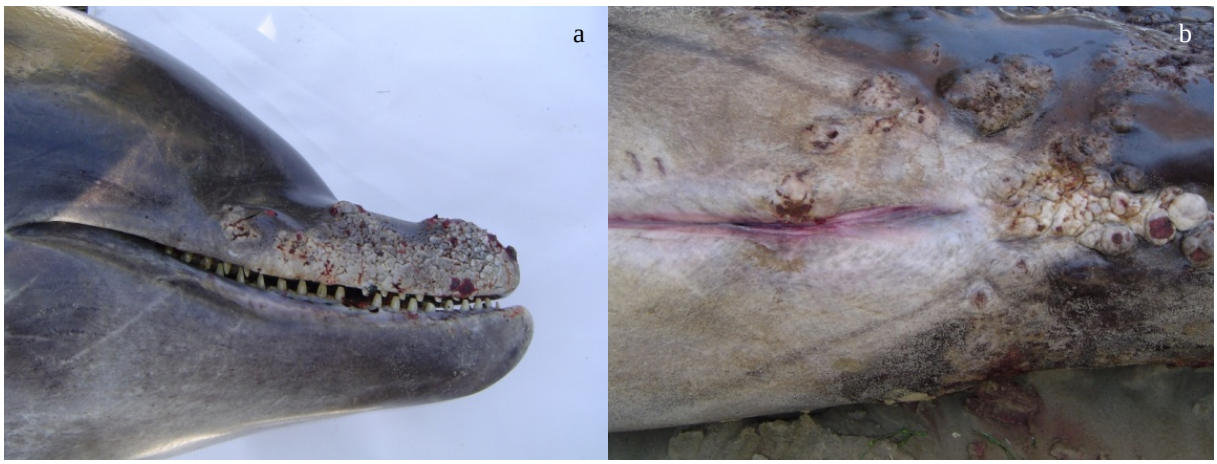

Figure 8 – Skin lesions of “Lobisomen” *Tursiops truncatus* (GEMARS 1259). (a) rostrum detail. (b) genital detail – ©Ignacio Moreno/GEMARS

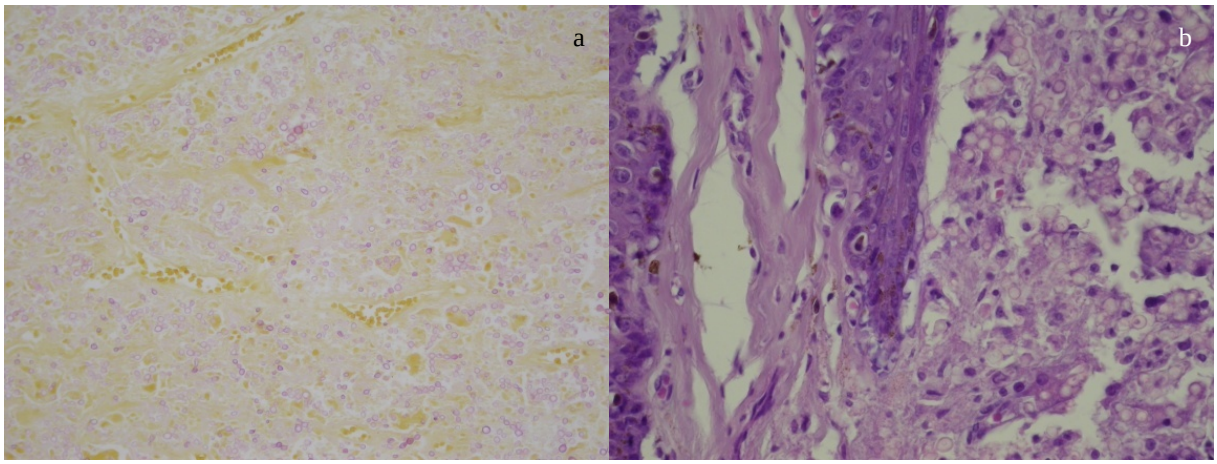

Figure 9 – “Lobisomen” *Tursiops truncatus* (GEMARS 1259). Skin: (a) presence of a large number of individual and chains of fungal cells well delineated and intensely stained in red, compatible with *Loboa loboi*. Gridley fungus stain. (b) large number of fungal structures poorly stained and connect each other with short “bridges” or tube-like structures forming chains of 2-5 cells each. Some individual cells and multiple buds are also seen. Hematoxylin and eosin stain. © Mauro Borba.

Figure 10 – Dolphin “Craquento” observed in March 2004 at Mampituba estuary. © Ignacio Moreno/GEMARS



Figure 11 – Stranded *Tursiops* GEMARS 1298. (a) – General view of skin lesions. (b) - Detail of one skin lesion. – © Paulo Ott/GEMARS