A summary of ongoing bowhead whale sensory research in Northern Alaska

[1]Cheryl Rosa, [2]J.G.M. Thewissen, [3]Takushi Kishida, [4]Sirpa Nummela, [1]Craig George, and [1]Robert Suydam
[1] Department of Wildlife Management, North Slope Borough, Box 69, Barrow, Alaska, USA
[2] Northeastern Ohio Universities Colleges of Medicine, Rootstown, Ohio
[3] Department of Zoology, Kyoto University, Kyoto, Japan
[4] Department of Biological and Environmental Sciences, University of Helsinki, Helsinki, Finland
Contact email: *Cheryl.Rosa@north-slope.org*

ABSTRACT

The North Slope Borough Department of Wildlife Management, in cooperation with several other institutions (Northeastern Ohio Universities Colleges of Medicine, Massachusetts Eye and Ear Infirmary, Kyoto University, University of Helsinki), has instituted a research program that is geared specifically towards investigating the sensory abilities of the bowhead whale (*Balaena mysticetus*). This work consists of four main projects that investigate audition, olfaction, gustation, and vision. Information produced by these projects will be used to help determine impacts to the species from industrial development and other anthropogenic sources, as well as provide critical anatomical baseline data. These projects are detailed and preliminary results are provided.

KEYWORDS: ARCTIC; AUDITION; *BALAENA MYSTICETUS*; BOWHEAD WHALE; GUSTATION; OLFACTION; SENSORY SYSTEMS; VISION

INTRODUCTION

The bowhead whale (*Balaena mysticetus*) population of the Bering, Chukchi, and Beaufort Seas (BCBS), while endangered, has been recovering since the cessation of commercial whaling. Recently, their arctic habitat has been experiencing a rapid increase in industrial activities, decrease in sea ice extent and thickness, and variability in environmental parameters. Anthropogenic activities such as oil and gas development and commercial fishing have the potential to create disturbance, noise, and chemical pollution, all of which have been shown to have detrimental effects on wildlife, including whales. This suite of increased human activities is becoming more prevalent as economic motivations dictate or as sea ice change opens access to previously closed locations. Bowhead whales in the Western Arctic were exposed to a number of oil and gas operations, primarily exploration, during the summers of 2006-8. Additional activity is expected in the future. Exploration activities include 2D and 3D seismic, site clearance and shallow hazards surveys, and support activities. Seismic evaluation is a critical component of this exploration, which has the potential to ensonify large areas of ocean. Several species of marine mammal and their prey, all of which may be impacted by exploration, occupy the area in question. These surveys often operate both day and night and are often conducted for weeks on end. Most sound from these surveys is directed vertically, however, a substantial amount radiates horizontally.

Marine mammals, including bowhead and beluga whales, are sensitive to anthropogenic sounds. Whales may deflect away from sounds produced during exploration, development and production. If whales are deflected from their migratory route, they may avoid important feeding areas or conversely submit themselves to injurious levels of sound in order to feed/mate/rest in areas that are biologically important. Seismic sound may interfere with inter- and intra-specific communication ("masking"). Furthermore, industrial sounds, especially those from seismic, have the potential to cause temporary or permanent threshold shifts (hearing loss). Finally, physical damage may occur to the auditory apparatus of exposed whales.

Industrial offshore discharges, such as drilling muds, cuttings, cement, black and gray water, cooling water, produced water from well testing and ballast water into the ocean, may impact whales. Traditional knowledge of Inupiat elders and hunters indicates that bowheads have a sense of "smell" and that human waste, other wastes with odors and tastes, and sediment plumes can deflect them from their migratory path. Deflection causes whales to expend energy and also may result in reduced accessibility to preferred feeding, resting and mating areas. This may

lead to higher mortality or lower birthrates in these species. Finally, deflection of whales, caused by either by noise or scent/sediment plumes, can reduce hunting success depending on where and when it occurs.

The subsistence-based communities of Alaska's North Slope depend, to a large extent, on bowhead whales for both culture and nutrition. The responsibility for management and conservation of bowhead whales falls to the Alaska Eskimo Whaling Commission (AEWC) and the National Marine Fisheries Service (NOAA, Department of Commerce) via the AEWC/NOAA co-management agreement (Tillman, 1980). Locally, however, Alaska Natives of the North Slope (through the Alaska Eskimo Whaling Commission) have maintained a well-organized subsistence hunt for bowhead whales, and scientists operating primarily through the North Slope Borough's Department of Wildlife Management have gained the trust and cooperation of the whalers and have produced a considerable body of literature (approximately 300 papers and reports) on fundamental aspects of bowhead biology, providing important background databases and tissue archives. The sensory research program is an extension of these efforts and is being promoted to provide a better understanding of the sensory world of the bowhead whale and the potential for impacts from sound, waste and other industrial discharges.

Audition

The Minerals Management Service (MMS) regulations (30 CFR 251) state that geological and geophysical activities cannot cause harm or damage to aquatic life, property or to marine, coastal or human environments. Mitigation measures related to seismic activities have been implemented in the BCBS region, to varying extents, by the oil and gas industry. However, currently, no protocols exist to assess the physiological effects of exposure (acute or chronic) of BCBS marine mammals to seismic disturbance. Development of plans to monitor for potential physiological impacts of seismic noise in bowhead whales is a challenge, in part, due to the lack of baseline data on the anatomy of the mysticete ear. This information is a necessary foundation for subsequent research on the potential physiological effects of sound. Once compiled, these data should serve as a good model for other mysticete species. The annual spring and fall subsistence bowhead hunt provide excellent access to fresh biological samples.

This sub-project was designed in two phases: the first designed to characterize the gross and histological anatomy of the mysticete ear and the second designed to document, via histological analyses, evidence of chronic or acute auditory damage that may occur secondary to exposure to anthropogenic noise. The project seeks to accomplish several goals: a) assess the basic anatomy of the mysticete ear, using the bowhead whale as a model. This work will include both gross (i.e., high resolution CT) and histological analyses; b) collect data in a manner that allows inclusion in "phase two" research investigating the effects of acute and chronic noise on cetaceans; and c) report results to appropriate governmental agencies, the scientific community, the International Whaling Commission (IWC) Scientific Committee and other interested/involved organizations.

Working closely with subsistence hunters, we have removed the auditory region from a number of whales (fetal, juvenile and adult). These tissues and structures were measured, dissected and characterized anatomically according to protocols developed for human auditory research (see below). Fixed tissues are being assessed histologically for the presence of pathologic changes compatible with acute and/or chronic auditory damage.

Middle ear investigations:

Sound propagation in water is different from that in air; in water the sound velocity is almost five times higher, caused by a wavelength that is five times longer than in air. Due to this, and other differences between the propagation characteristics of air and water, it is evident that the general land mammal hearing mechanism is not functional in water. Currently, the hearing mechanism of mysticetes is poorly understood. "Hearing mechanisms", as used herein, refer to the sound path from the surface of the animal to the cochlea of the inner ear. The terrestrial mammalian sound path, through the outer ear canal and the tympanic membrane and middle ear ossicle vibrations, is not a functional sound transmission path in underwater hearing. The recently suggested mechanism for odontocetes, through the lower jaw fat pad further to the tympanic bone lateral wall and the middle ear ossicle vibrations, is not a functional mechanism in mysticete sound transmission.

Bowhead whales produce sounds near the lower end of the frequency spectrum audible to humans (summarized by Wartzok and Ketten, 1999) and they use these sounds for communication and possibly for navigation (George et al., 1989). The frequencies that an animal can hear depend, to a large extent, on the inner and

middle ear. Bowhead whales are believed to be specialized for low frequency sound reception (Wartzok and Ketten, 1999), and models have been constructed to analyze inner ear morphology and hearing in North Atlantic right whales (*Eubalaena glacialis*, Parks et al., 2007), which are closely related to bowhead whales. The anatomy and scaling relations of the middle ear also constrain the sound reception abilities of cetaceans (Nummela et al., 1999), but this has not been studied in bowhead whales.

The bowhead whale uses low sound frequencies, mainly 400 Hz to a few kHz. For these frequencies the sound wavelengths underwater are considerably long (e.g., a sound of 1000 Hz has a wavelength of 1.5 m, a sound of 500 Hz has a wavelength of 3 m). The reception of such low sounds with such long wavelengths suggests the receptive organ cannot be a very small structure. However, apparently the middle ear structures play a part in sound transmission to the inner ear, and hence, detailed anatomical dissection of the peripheral auditory structures and associated analyses are being conducted.

Our objectives are to study the middle ear of Bowhead whales, using anatomy and scaling relations to provide constraints on the auditory abilities of these whales, and to assess whether middle ear transmission in bowheads is similar to that of toothed whales (Nummela, 1995; Hemila et al., 1995). It is, at present, unclear how sound is transmitted through the mysticete middle ear, although models are available that clarify this in odontocetes (Hemila et al., 1999) and ancestral whales (Nummela et al. 2004), and study of bowhead ears will be used to assess the appropriateness of the existing models.

In 2008, we studied the ear regions of the adult specimens 08B10, 08B11, and 08B13 through gross dissection. The specimens 08B10 and 08B11 were studied in the field. As a result of the whale's position (ventral recumbency), we removed the soft tissues surrounding the tympano-periotic complex ventrally, laterally and caudally. After that, the tympanic bone was removed and the soft and bony structures within and around the middle ear cavity were studied. From the specimen 08B13, a large caudal block of the head was removed including the squamo-occipital part of the skull with the whole tympano-periotic complex and skull areas surrounding it (Figure 1). The anatomical structures in this block were studied more closely in the lab. The external auditory meatus containing the ear wax plug was found intact. The tympanic membrane, also called 'the glove finger' in mysticetes, was cut open and its relationship to the middle ear ossicular chain was documented (Figure 2). The structures within and around the middle ear cavity were also studied, mainly the sinuses and the mastoid process of the tympano-periotic complex. Special attention was paid to the orientation and connections of the middle ear ossicles in the middle ear cavity.

The data received from the studies of these adult specimens will be used in studies focusing of sound transmission mechanisms in bowhead whales, and in mysticetes in general. They will also be used in comparative studies dealing with odontocete and mysticete ear anatomy, and with sound transmission mechanisms of species in these two cetacean groups.

We also continued our work on the fetal head of the specimen 07B16F. In this specimen, the left side was frozen, and the right side was stored in formalin. Dissections of the ear region on both sides were carried out, and measurements were taken on the skull, the lower jaw, and the tympanic and cochlear dimensions, as well as the eye orbit. These data will be used in a survey studying the growth patterns of skull structures in bowheads of different ages.

Inner ear investigations:

While most anatomical studies on the ear of cetaceans concern toothed whales, there is limited anatomical information available for mysticetes (e.g., Fraser and Purves, 1960, and Purves, 1966, on fin whales). Modern anatomical studies using imaging usually focus on odontocetes, but some information on mysticete ears is available (e.g, Ketten and Wartzok, 1990; summarized in Wartzok and Ketten, 1999). Studies of the inner ear of bowhead whales have been used to infer its auditory abilities (Norris and Leatherwood, 1981) and more detailed work proposed here will refine and test results from previous work.

Work is underway to collect and preserve the ear regions of fetal, juvenile, and adult bowhead whales. These ears are being subjected to standardized morphometric analysis and CT-scan study (Figure 3). CT scan-data are being used to document the bony morphology of the cochlea and semicircular canals (located in the petrosal part

of the ear region). CT-scan studies of the cochlea have been used in the past to determine frequency ranges of cetacean ears (Ketten and Wartzok, 1990; Ketten, 1992). Data on specimens that include soft tissue can be used to test some of the frequency-range predictions of the cochlear models in bowhead whales and access their variation on the basis of large sample size and with more advanced CT methods than those available more than a decade ago. Importantly, study of the membranous labyrinth of the inner ear can be used to assess ear trauma. The membranous labyrinth contains the Organ of Corti, the part of the ear where the mechanical waves (caused by sound) are transduced into electrical impulses that are passed on to the brain. Histological study of the membranous ligament will allow us to assess whether frequency reception has been damaged, whether this damage was traumatic or gradual, and whether the damage was recent or older (Sugawara et al., 2005).

CT scan data will also be used to study the semicircular canals (also located in the petrosal part of the ear region), another sense organ based on maculae (and assessed for trauma in the histological analysis). It has been determined that bowhead whales have semicircular canals that are larger than those of many other cetaceans (Spoor et al., 2004), and the semicircular canals are an important anatomical difference between the ears of bowheads and other whales.

Tissues were dissected so as to preserve all structures of the middle and inner ear, including a piece of the auditory nerve in the internal auditory meatus. Tissues were fixed by immersion in buffered solutions of mixed aldehydes (paraformaldehyde and glutaraldehyde) and then decalcified in EDTA mixed with small amounts of fixative. Small holes were opened into the middle ear space to enhance mixing of fluids. Ultimately, several different embedding and staining approaches will be applied to the whale ears. These will include: celloidin embedding, paraffin or polyester wax embedding, and wet dissection of the organ of Corti, followed by immunostaining for hair cells and nerve fibers to reveal details of the cellular architecture of the sensory epithelium, including the condition of the stereociliary bundles on the hair cells and the degree of neuronal degeneration (Maison et al., 2006). This work will be performed at Massachusetts Eye and Ear Infirmary. The tissue analysis consists of two stages. The first is a qualitative assessment of all structures in the middle and inner ear. The second will involve careful quantification of the degree and spatial distribution of any histopathologies observed in the first stage.

<u>Olfaction</u>
Gross anatomy

It is a widespread perception that whales, dolphins, and porpoises have a minimal sense of olfaction or lack it altogether (Dehnhardt, 2002; Pihlstrom, 2008), a very unusual feature among mammalian orders. Aquatic life is often thought to be at the root of the absence of a sense of smell, since airborne odorants appear irrelevant to an airbreather that lives and feeds below the surface. In investigated toothed whales (odontocetes), the nervous structures that mediate olfaction are absent: there is no cranial nerve I, no olfactory bulb, and no olfactory tract (Oelschläger and Oelschläger, 2008). However, there are scattered observations that in (some) baleen whales (mysticetes) some of these nervous structures remain (Watkins and Wartzok, 1985; Oelschläger and Oelschläger, 2008). The olfactory bulb in some fetal mysticetes has been shown to be large (Oelschläger and Buhl, 1985). This observation, however, is not inconsistent with strongly reduced olfaction in the adult, given that in prenatal life archaic parts of the brain are often more complex than postnatally.

Anecdotal evidence from behavioral observations suggests that bowhead whales can detect airborne odorants (Cave, 1988), but the olfactory parts of their brains are small (at least in their close relatives, Pilleri, 1964). Smell can only serve to identify molecules suspended in air, and would thus seem of little use in marine mammals. However, concentrations of oceanic plankton in the ocean produce a peculiar aroma in the air above them, mostly caused by dimethyl sulfide and pyrazines (Nevitt, 1999), a cue used by some krill-eating birds to detect their prey (petrels, albatrosses, Hieronymus, 2007). For aquatic krill-eaters, olfaction is a useful prey-detecting device.

Anatomy also suggests that a sense of smell occurs in Bowhead whales. There are two depressions on the palate, immediately behind the upper lip in the midline (pers. obs.). In other mammals, such as deer and dogs, these two depressions lead to the ducts of the Organ of Jacobson (also called the *vomeronasal organ*), an organ that registers airborne stimuli different from those in the olfactory epithelium (Eisthen and Schwenk, 2008). In the closest relatives of whales, artiodactyls, the vomeronasal organ is very important in several sexual functions: male deer, for instance, use it to sense the reproductive status of females, by exposing their palate to the air, so called

Flehmen response. Although the vomeronasal organ is clearly absent in some cetaceans (Pihlstrom, 2008), bowhead whales have never been investigated and it is possible that they retain vomeronasal epithelium. It is our objective to investigate the anatomy of the Bowhead olfactory system and, by comparison with other mammals, investigate whether these whales are likely to have olfaction. We define olfaction traditionally as the ability to detect airborne odors with Cranial Nerve I.

We removed the brain of a bowhead whale landed in Barrow during the fall of 2008 (08B11). The olfactory bulb is encased by massive bone at the end of a bony canal for the olfactory tracts that reaches rostral from the cranial cavity. Using a chainsaw, we cut a block out of the center of the skull, roughly measuring 15x20x30 cm, and consisting of massive bone dorsal, ventral, and lateral to the olfactory tract. We poured buffered formalin in the tunnel for the tracts, to stabilize the bulb. Then, we used a reciprocating electrical construction saw with bi-metal blades to reduce the bone, and dissected the bulb out of its protective sleeve of dura mater. The left and right bulbs are separated by intervening dura and dural sinuses. Only half of the bulb was retrieved, and it was weighed. This weight (1.6 g) was doubled (to account for the entire, bilateral, structure) and might be a slight underestimate of the bulb, as brain specimens fixed in buffered formalin tend to lose up to 10% of their weight (Bauchot, 1967). The brain of this whale weighed 2.95 kg. The bulb was embedded in paraffin, and attempts were made to cut it, but these failed due to the hardness of the specimen. It was extracted from the paraffin and decalcified, and re-embedded and cut. Sections were Nissl stained to visualize neural structures histologically.

We found that the olfactory bulbs in the bowhead whale are at the end of a 6 cm long bony canal that extends anterior from the cranial cavity toward the nasal passages. This canal tunnels through a massive section of bone (Figure 5). The olfactory bulb is sheathed in dura, and the dura is perforated by many nerves, together representing CN I. Left and right olfactory bulbs are roughly oval in shape, 4.5 cm in width, and 1.5 cm in height (Figure 6), much larger than the cribirform plate in a human. The olfactory bulb weighs 3.2 g, or 0.105% of brainweight.

Stephan et al. (1981) did a comprehensive study of relative sizes of different parts of the brain in primates. They found that there a number of Old and New World Monkeys in which the olfactory bulb makes up approximately 0.1% of brainweight, such as macaques (0.09%), baboons (0.14%), spider monkeys (0.10%) and sakis (0.10%). The olfactory bulb in humans is much smaller (0.008%). Olfaction plays an important role in social behavior and food gathering in Old and New World Monkeys, and we suggest that olfaction is important in bowhead whales, as well.

Histology

We plan to further investigate Bowhead olfaction by means of a histological study of the olfactory epithelium of the Bowhead olfactory passages in the nasal cavity, and a histological study of the olfactory bulb. These studies will result in embedded epithelial and nervous tissues that will be microtomed and stained for microscopic investigation. We will use common histological stains (Trichrome, H&E), but may also use immunohistochemical techniques. We will also study whether the vomeronasal organ is present by investigating its neural connections, the accessory olfactory bulb in the brain, as well as study the acuity of the olfactory system by means of a microscopic study of sections of parts of the brain dedicated to olfaction (the olfactory bulb).

Olfactory receptor gene research

From the anatomical point of view, baleen whales have reduced and toothed whales have lost their main olfactory bulbs (Philstrom 2008). In addition, genetic studies revealed that a large-scale degeneration of olfactory receptor genes occurred when whales migrated from the land to the sea (Kishida et al. 2007, McGowen, 2008). However, compared to toothed whales, baleen whales still have maintained their olfactory receptors. Our proposed genetic work involves estimating the olfactory receptor repertoire of a bowhead whale based on the PCR-based method to understand the genetic basis of bowhead olfaction.

Olfactory receptors in the bowhead whale genome will be collected using the protocol modified from Kishida et al. (2007). We investigated nine olfactory receptors, which were selected randomly from the bowhead whale genome, and showed that 56% of the bowhead olfactory receptors had lost function. The pseudogene proportion of the bowhead olfactory receptor repertoire (56%) is relatively small compared to that of toothed whales

(Kishida et al. 2007, McGowen, 2008). It would be expected that bowhead whales have relatively well-developed sense of smell compared to the other whales because of the relatively lower proportion of pseudogenes among the bowhead olfactory receptor repertoire. However, the current sample size is too small to get reliable results, thus we plan investigate a greater number of bowhead olfactory receptors to characterize the olfactory receptor repertoire of bowhead whales.

Gustation

Little is known about the sense of taste in cetaceans. Sonntag (1922), Yamasaki et al. (1978), and Pfeiffer et al. (2001) studied cetacean tongues finding that few taste receptor are present, but experimental studies (Kuznetsov, 1990; Nachtigall and Hall, 1984) have shown that some cetaceans can detect sour and bitter "flavors" at concentration levels similar to those of humans, but was less sensitive to sweet flavors. Nothing is known about the sense of taste in bowhead whales, and very little is known about other baleen whales. We are presently investigating the anatomy of the tongue histologically, in order to determine whether taste buds are present.

The tongue of a bowhead whale is large, approximately 1.5 m long and more than 1 m wide, and most of it is smooth, unlike other mammals. We will examine the surface of the tongues with a hand lens, and excise all areas with relief. We will investigate these tissue blocks histologically and determine whether there are tastebuds on the Bowhead tongue. Tastebuds are distinctive histologically, but have not been recognized in bowheads (Haldiman and Tarpley, 1993). Of these areas, we will make histological preparations of those areas of the tongue that have small pits which are indicative, in other mammals, of tastebuds. The presence of tastebuds is an indicator of the ability to taste, although it does not give clues to sensitivity and specificity of this sense.

Vision

In most mammals, there is a single area on the retina (the light sensitive area of the eyeball) with a high concentration of cells that process visual information: the fovea (Hughes, 1977). In some cetaceans, there is not just one, but two foveae (Mass and Supin, 2002). One of the foveae is used specifically for producing focused vision in air, whereas the other for vision underwater. However, in the gray whale (*Eschrictius robustus*), a relative of the bowhead, there is only one fovea. Bowhead whales may feed at the surface, and it is thus possible that two foveae occur in these whales too. The presence of two foveae would imply that bowheads have good vision above and below the water surface, and is consistent with bowheads using above-surface landmarks when migrating or finding open water for breathing. Although there are some studies of bowhead retinas (Zhu, 1998; Zhu et al., 2001), the presence of foveae has not been studied.

Another important indicator of using vision as a close-range sense organ (for instance for locating prey and breathing holes) is the ability to see stereoscopically. There are several reports on the stereoscopic abilities of other cetaceans (summarized in Mass and Supin, 2002), and it has been suggested that their eyes are highly mobile and able to protrude (Abdelbaki and Haldiman, 1986), consistent with an overlap of the visual fields. Stereoscopic vision will be studied by analyzing the neural pathways at the point where the optic nerve reaches the brain: the optic chiasm. In animals that lack stereoscopic vision, nearly all fibers from the left eye cross to the right side of the brain (i.e. they project contralaterally), whereas in animals with good stereoscopic vision, a large number of fibers from the right eye passed through the optic chiasm to the right side of the brainstem (they project ipsilaterally). Bowhead eyes are unusual in that they are one of the few organs in the whale's body that is not covered by blubber. As in all mammals, the eye is close to the body's core temperature, but it is also directly exposed to the arctic water in which the whale swims. The enormous temperature gradient across the exposed part of the eye, the cornea, combined the highly abrasive nature of their environment (floating ice crystals, sediment particles) suggest that the cornea is exposed to disruptive forces different from other mammals. Basic measurements on the cornea of bowhead whales were published by Zhu (1998), who noted that its outer layer is keratinized.

Our research involves studying the cornea histologically, in order to evaluate the effect that injuries (scratches, oil) may have on it. The ganglion cells of the retina will be studied in order to determining the number of foveae, and thus assess the Bowhead's ability to see above and below the water level. We will use retrograde staining of axons through the optic chiasm to determine whether whales can see stereoscopically. During this coming season, we will refine the retrograde staining technique used to preserve the optic chiasm. Paraformaldehyde

is a possible choice, as formalin has not been useful. Once this optimal method is found, histological analyses will progress.

SUMMARY

Anthropogenic activities such as oil and gas development and commercial fishing and shipping have the potential to create environmental disturbance, noise, and chemical pollution, all of which may impact wildlife, including whales. These activities are expanding rapidly in the Arctic, therefore, it is important to determine impacts, so that injury to marine wildlife can be avoided or appropriate and effective mitigation measures can be developed.

Migratory deflections caused by seismic sound, shipping or discharged wastes in the water may result in avoidance of important feeding areas or, conversely, whales exposing themselves to injurious levels of sound in order to feed/mate/rest in areas that are biologically important. Deflection may also result in increased energy expenditure. All of these factors may lead to higher mortality or lower birthrates in these species. Seismic sound may interfere with inter- and intra-specific communication ("masking") or cause temporary or permanent threshold shifts (hearing loss) and other physical damage to the auditory apparatus of exposed whales.

The NSB-DWM's sensory research program has been developed around these concerns. These studies will provide a better understanding of the sensory world of the bowhead whale and the potential for impacts from sound, waste and other industrial discharges. These data will also provide needed baseline information to assist in impact analysis and the development and evaluation of mitigation measures.

ACKNOWLEDGEMENTS

We thank the Alaska Eskimo Whaling Commission and local hunters for their support. We especially thank the Captains' association and hunters from Barrow for providing us access to whales for examinations and sampling. Cyd Hans, Josh Bacon, Brian Person, Michael Pederson and Ambrose Leavitt provided invaluable assistance in the field. Dolores Vinas, Molly Spicer and Bertha Akootchook provided logistical support. The North Slope Borough provided financial support. Finally we thank Edward Itta (Mayor of the North Slope Borough) and Taqulik Hepa (Director of the North Slope Borough Department of Wildlife Management) for their encouragement and support.

REFERENCES

Abdelbaki, Y. Z., and J. T. Haldiman. 1986. Chapter 6—Eye, Pp. 133-144 in: Continued studies on the determination of the morphology of the skin, respiratory system, urinary system, brain, and eye of the Bowhead Whale, *Balaena mysticetus* (J. T. Haldiman, ed.). Dept. Wildlife Management, North-Slope Borough, Barrow, Alaska.

Bauchot, R. 1967. Les modifications du poids encephalique au cours de la fixation. J.Hirnforschung 9:253-283.

Cave, A J E. 1988. Note on olfactory activity in mysticetes." Journal of Zoology 214:307-311.

Dehnhardt, G. 2002. Sensory systems. Pp. 116-141. In R. Hoelzel (ed.) Marine Mammal Biology. Blackwell Publ., Oxford, UK.

Eisthen, H. L., and K. Schwenk. 2008. The chemical stimulus and its detection. Pp. 35-41 in: Sensory Evolution on the Threshold: Adaptations in Secondarily Aquatic Vertebrates (J. G. M. Thewissen and S. Nummela, eds.) University of California Press.

Fraser, F. C. and Purves, P. E. 1960. Anatomy and function of the cetacean ear. Proc. Roy. Soc. London, B, 152:62-77.

George, J., C. Clark, G. Carroll and W. Ellison. 1989. Observations on the ice- breaking and ice navigation behavior of migrating bowhead whales (Balaena mysticetus) near Point Barrow, Alaska, Spring 1985. Arctic 42:24-30.

Haldiman, J.T., Tarpley, R. J. 1993. Anatomy and Physiology. In The Bowhead Whale (J. J. Burns, J. J. Montague, C. J. Cowles. Spec. Publ. 2, Soc. Mar. Mam.

Hemila, S., Nummela, S. and Reuter, T. 1995. What middle ear parameters tell us about impedance matching and high frequency hearing. Hearing Res 85:31-44.

Hemila, S., Nummela, S. and Reuter, T. 1999. A model of the odontocete middle ear. Hearing Res 133:82-97.

Hieronymus, T., 2007. Comparative anatomy of chemical senses in aquatic birds. Pp. 83-94 in: Sensory Evolution on the Threshold: Adaptations in Secondarily Aquatic Vertebrates (J. G. M. Thewissen and S. Nummela, eds.) University of California Press.

Hughes, A. 1988. The topography of vision in mammals of contrasting life style: comparative optics and retinal organization. Pp. 613-765, in Handbook of Sensory Physiology VII/5 (F. Crescitelli, ed.). Springer Verlag.

Ketten, D. R. 1992. The marine mammal ear: specializations for aquatic audition and echolocation. Pp. 717-754 in D. Webster, R. Fay, and A Popper (eds.) The Biology of Hearing, Springer Verlag, New York.

Ketten, D. R. and Wartzok, D. 1990. Three dimensional reconstructions of the dolphin ear. Pp. 81-105. In J. Thomas, and R. Kastelein. Sensory abilities of cetaceans. Plenum Press New York.

Kishida, T., Kubota, S., Shirayama, Y., and Fukami, S. (2007) Biol. Lett. 3: 428-430.

Kuznetsov, V. B. 1990. Chemical sense in dolphins: quasi-olfaction. pp. 481-503. IN J. A. Thomas and R. A.

Kastelein (eds.). Sensory abilities of cetaceans: laboratory and field evidence. Plenum, New York.

Maison, S.F., Rosahl, T.W., Homanics, G.E. and Liberman, M.C. 2006. Functional role of GABAergic innervation of the cochlea: phenotypic analysis of mice lacking GABA(A) receptor subunits alpha 1, alpha 2, alpha 5, alpha 6, beta 2, beta 3, or delta. J Neurosci 26:10315-10326.

Mass, A. M., and A. Ya. Supin. 2003. Vision. Pp. 1280-1293, in: Encyclopedia of Marine Mammals (W. F. Perrin, B. Würsig, J. G. M. Thewissen, eds.), Academic Press, San Diego.

McGowen, M.R. 2008. Syst. Biol. 57: 574-590.

Nachtigall, P. E. and R. W. Hall. 1984. Taste reception in the bottlenosed dolpin. Acta Zool. Fennica 172:147-148.

Nevitt, G. A. 1999. Foraging by seabirds on an olfactory landscape. American Scientist 87:245-253.

Norris, J.C. and and Leatherwood, S. 1981. Hearing in the Bowhead whale, Balaena mysticetus, as estimated by cochlear morphology. Hubbs Sea World Research Institute Technical Report 81-132:15.1-15-49.

Nummela, S. 1995. Scaling of the mammalian middle ear. Hearing Res 85:18-30.

Nummela, S., Reuter, T., Hemila, S., Holmberg, P. and Paukku, P. 1999. The anatomy of the killer whale middle ear (*Orcinus orca*). Hearing Res 133:61-70.

Nummela, S., Wagar, T., Hemila, S. and Reuter, T. 1999. Scaling of the cetacean middle ear. Hearing Res 133:71-81.

Oelschläger, H. H. A., and J. S. Oelschläger. 2008. Brain. Pp. 134-149 in W. F. Perrin, B. Würsig, and J. G. M. Thewissen, Encyclopedia of Marine Mammals, Elsevier, Amsterdam, Netherlands.

Oelschläger, H. A., and E. H. Buhl. 1985. Development and rudimentation of the peripheral olfactory system in the harbor porpoise Phocoena phocoena (Mammalia, Cetacea). J. Morphol. 184:351-360.

PfeifferD. C., A. Wang, J. Nicholas, C. J. Pfeiffer. 2001. Lingula ultrastructure of the long finned pilot whale (Globicephala melas). Anatomia, Histologia, Embryologia 30:359-365.

Philstrom H (2008) Comparative anatomy and physiology of chemical senses in aquatic mammals. In "Sensory evolution on the threshold" (eds. J.G.M. Thewissen and S. Nummela), pp95-109, Univ. of California Press, Berkeley.

Pilleri, G, and M. Gihr. 1970. The central nervous system of the mysticete and odontocete whale. Investigations in Cetacea (Berne) 2:87-135.

Sonntag C. F. 1922. The comparative anatomy of the tongues of the mammalia, VII, Cetacea, Sirenia, and Ungulata. PRoc. Zool Soc. London 44:639-657

Spoor, F., Bajpai, S., Hussain, S.T., Kumar, K., and Thewissen J.G.M. 2002. Vestibular evidence for the evolution of aquatic behaviour in early cetaceans. Nature 417:163-166 F.

Stephan,H., H. Frahm, and G. Baron. 1981. New and revised data on volume of brain structures in insectivores and primates. Folia Primatologica 35:1-29.

Sugawara, M, G Corfas, and AC. Liberman. 2005 Influence of supporting cells on neuronal degeneration after haircell loss. J. Assoc. Res. Otolaryn. 6:136-147

Tillman, 1980. The bowhead whale: whaling and biological research. Marine Fisheries Review 42:1-5.

Wartzok, D. and D. R. Ketten, 1999. Marine mammal sensory systems, pp. 117-175, in: J. E. Reynolds and S. A. Rommel (eds.) Biology of Marine Mammals. Smithsonian Institution Press.

Watkins, W. A., and D. Wartzok. 1985. Sensory biophysics of marine mammals. Marine Mammal Science 1:219-260.

Yamasaki, F., S. Komatsu, and T. Kamiya. 1978. Papillary projections at the lingual margin in the striped dolphin Stenella coeruleoalba, with special reference to their development and regression. J. Morph. 157:33-47

Zhu, Q. 1998. Studies on the eyes of the Bowhead Whale (*Balaena mysticetus*), ringed seal (*Phoca hispida*), and Caribou (*Rangifer tardigradus*). Ph. D. Dissertation, Chinese Acad. Sci.

Zhu, Q., D. J. Hillmann, and W. G. Henk. 2001. Morphology of the eye and surrounding structures of the Bowhead Whale, *Balaena mysticetus*. Marine Mammal Science 17:729-750.

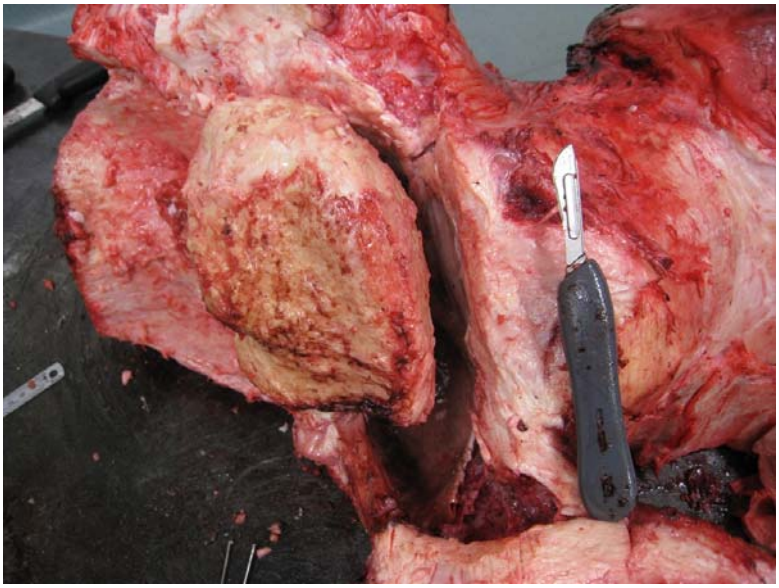

Figure 1. Bowhead whale tympanic bone with medial and pterygoid sinuses.

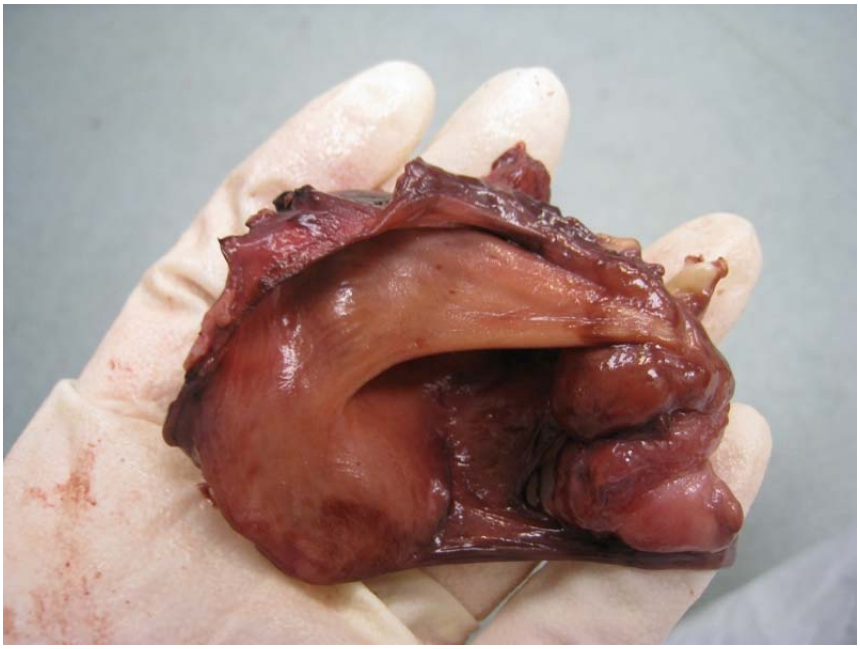

Figure 2. Bowhead whale tympanic membrane, medial view.

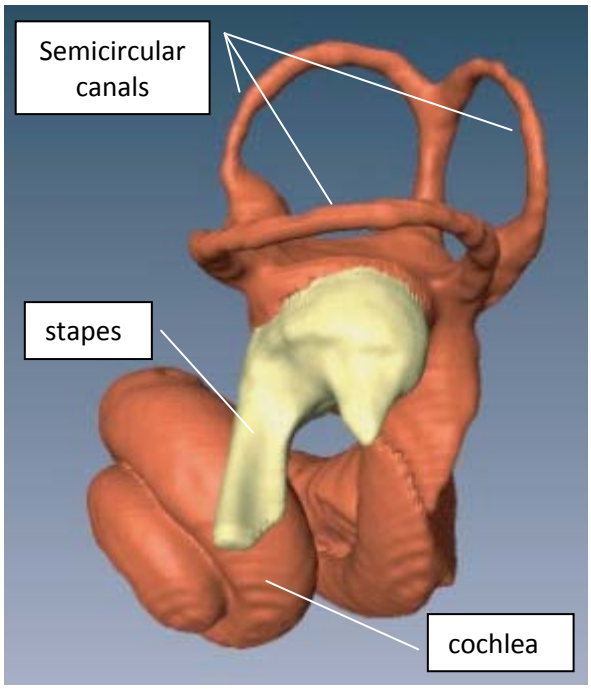

Figure 3. Bony labyrinth of the ear, including the organ of hearing (cochlea) and balance (semicircular canal), and one of the ear ossicles (stapes, broken here). This image was generated based on CT-scans of a Bowhead whale periotic bone. Sections were compiled by computer into a three dimensional view.

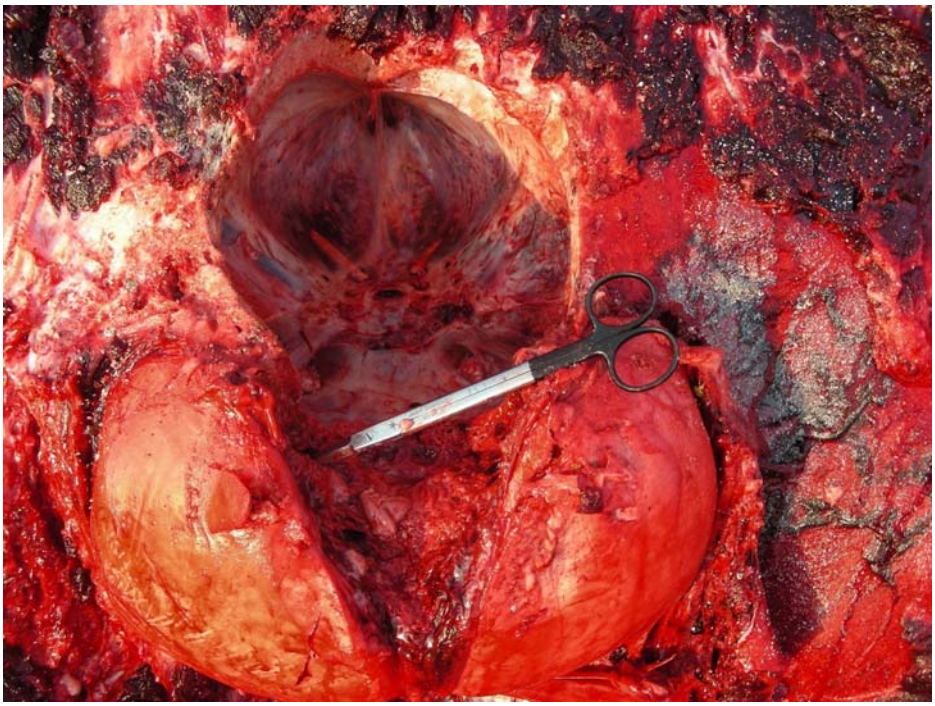

Figure 4. Bowhead whale braincase, brain removed.

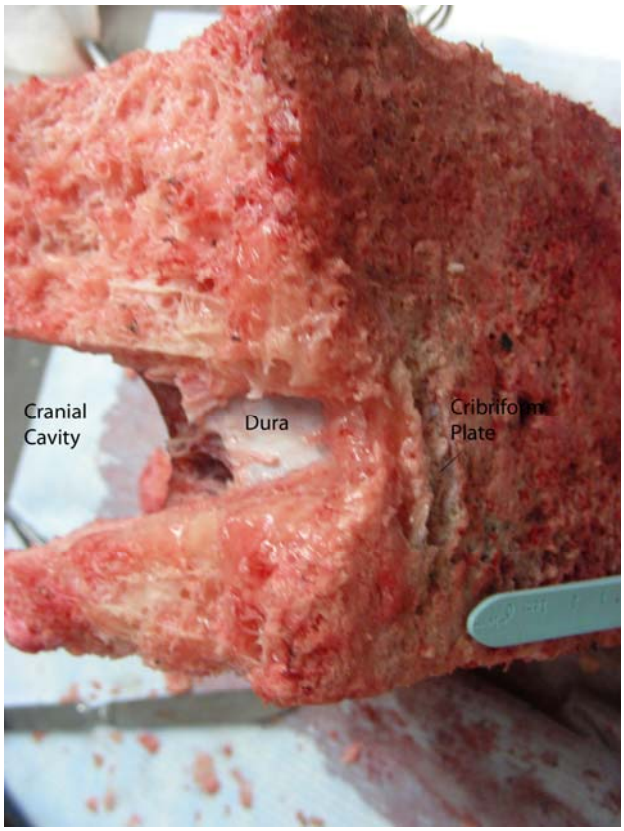

Figure 5. Block dissection of skull region anterior to cranial cavity, seen from rostroventral. Cranial cavity is behind block, dura (white) covers olfactory tract. Damaged cribriform plate can be seen on cut surface.

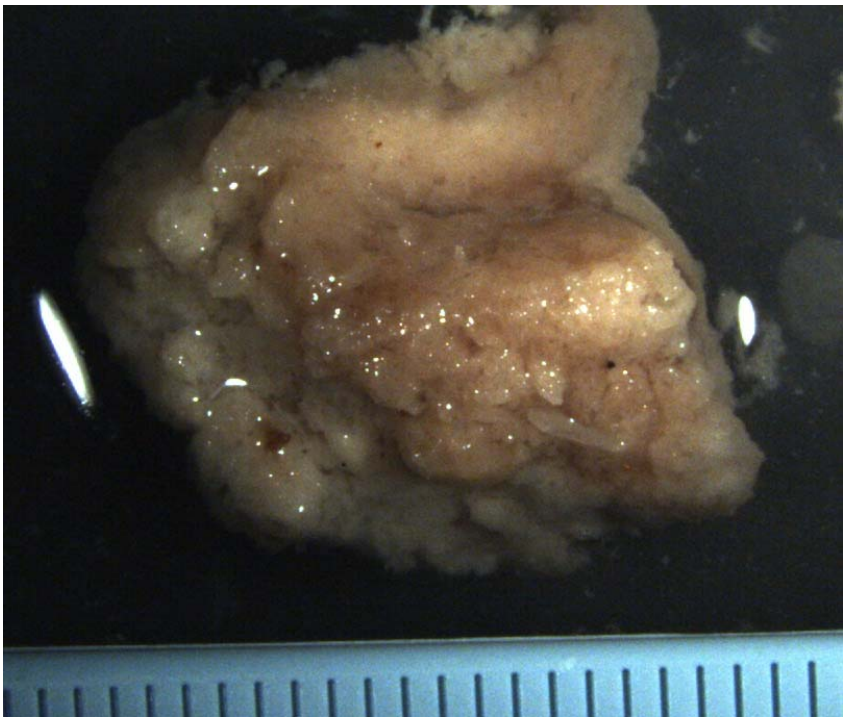

Figure 6. The olfactory bulb of a bowhead whale (scale in mm).